

Exploring the Diagnostic Value of Oral Tissue Biopsy in Unveiling Amyloidosis: An Investigation into Oral Manifestations and Diagnostic Applicability

¹Dr. Sajid Ali Majeedano, ²Dr. Zobia Nissa Memon, ³Dr. Shahzaman Memon, ⁴Dr Farwa Rubab, ⁵Dr Qura tul ain Manzoor, ⁶Dr Muhammad Salman Rashid, ⁷Khurram Shahzad, ⁸Kashif Lodhi

¹Assistant Professor, Dept: of Oral Medicine, Muhammad Dental College, Ibn-e-Sina University, Mirpurkhas

²Senior Lecturer, Oral Pathology Department, Isra Dental College, Isra University, Hyderabad

³Assistant Professor, Department of Oral Pathology, Muhammad Dental College, Ibn-e-Sina University Mirpurkhas,

⁴Senior Registrar Oral & Maxillofacial Surgery, Rashid Latif Medical & Dental College, Lahore

⁵Senior Registrar Operative Dentistry Rashid Latif Dental College Lahore,

⁶Assistant Professor Avicenna Dental College Lahore,

⁷HIESS, Hamdard University, Karachi, Pakistan,

⁸Department of Agricultural, Food and Environmental Sciences. Università Politcnica delle Marche Via Brece Bianche 10, 60131 Ancona (AN) Italy,

ABSTRACT:

Background: Amyloidosis, a category of illnesses distinguished by aberrant protein deposition, frequently appears with a variety of medical symptoms. Because oral tissues are easily accessible and have high diagnostic potential, they have emerged as a possible path for amyloidosis detection. The purpose of the research is to investigate the diagnostic utility of oral tissue biopsy in unravelling amyloidosis, with a focus on oral symptoms, and to assess the usability of this diagnostic method.

Aim: The major goal of this study is to determine the diagnostic accuracy of oral tissue biopsy for amyloidosis. This study intends to improve our understanding of how amyloidosis presents in the oral cavity by looking into the many oral symptoms associated with the illness. Furthermore, the study aims to determine the practicability and dependability of oral tissue biopsy as a diagnostic tool for amyloidosis.

Methods: A detailed clinical research will be carried out on a group of individuals with suspected or confirmed amyloidosis. Oral tissue specimens will be taken and analyzed histopathological and immunohistochemically to detect amyloid deposits. Symptoms that are clinical in the oral cavity will be well recorded. The study will use statistical analysis to assess the sensitivity, specificity, and overall diagnostic reliability of oral tissue biopsy in the setting of amyloidosis.

Results: The findings will give information on the prevalence and patterns of amyloidosis-related oral symptoms. Furthermore, the diagnostic performance of an oral tissue biopsy, particularly its specificity and sensitivity, will be investigated. The relationship between oral findings and systemic disease development will be investigated, adding important information to our knowledge of amyloidosis.

Conclusion: The research presented here emphasises the importance of oral tissue biopsy as a diagnostic tool for amyloidosis, providing information on its efficacy and accuracy in identifying the illness. The observed oral signs may serve as important markers for early diagnosis and treatment. The discoveries will help to further our understanding of amyloidosis and open the path for more effective diagnostic techniques, perhaps enhancing patient outcomes.

Keywords: Amyloidosis, Oral Manifestations, Diagnostic Value, Tissue Biopsy, Histopathology, Immunohistochemistry, Sensitivity, Specificity, Clinical Study.

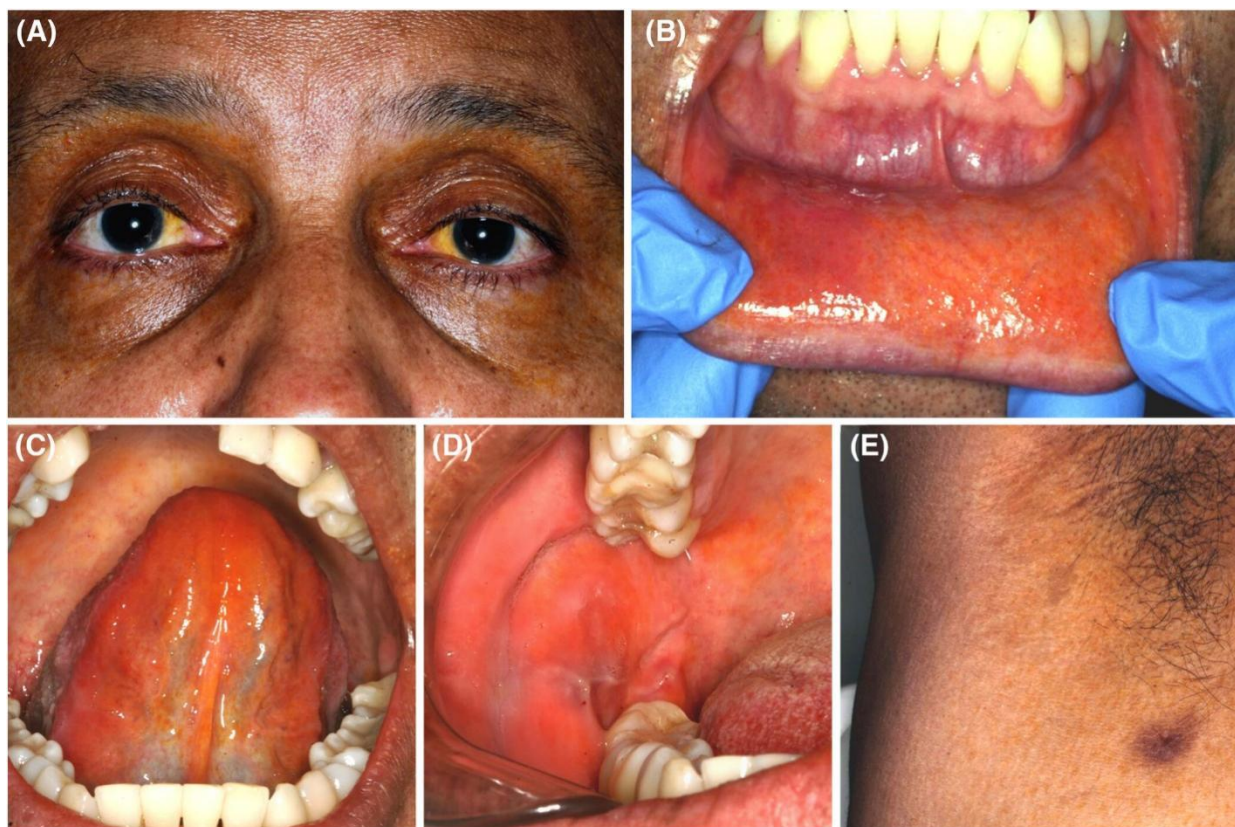
INTRODUCTION:

Amyloidosis is a broad category of illnesses defined by the extracellular deposition of aberrant protein aggregates known as amyloid fibrils. These fibrils can collect in many organs and tissues throughout the body, causing a variety of clinical symptoms [1]. While amyloidosis has been widely researched in systemic settings, oral symptoms have emerged as promising diagnostic markers [2]. This study seeks to investigate the diagnostic efficacy of oral tissue biopsy in detecting amyloidosis, offering insight on the complex oral symptoms and the application of this diagnostic method.

Amyloidosis is classified into various subgroups, each with its own clinical presentation and underlying pathogenic processes [3]. Amyloid fibril deposition can develop on its own or as a result of other systemic diseases, making diagnosis difficult [4]. Traditional diagnostic procedures rely heavily on tissue samples from afflicted organs such as the kidney, liver, or gastrointestinal tract. However, recent research has focused on the mouth cavity as a possible source of useful diagnostic information [5].

Amyloidosis can cause a variety of oral symptoms, including damage to the tongue, buccal mucosa, palate, and gingiva. These manifestations may be localized or systemic, with symptoms ranging from minor discomfort to severe functional impairment [6]. Common oral manifestations include macroglossia, xerostomia, ecchymosis, and, in certain cases, spontaneous bleeding. The variety of these presentations warrants a thorough investigation of the diagnostic potential of oral tissue biopsy [7].

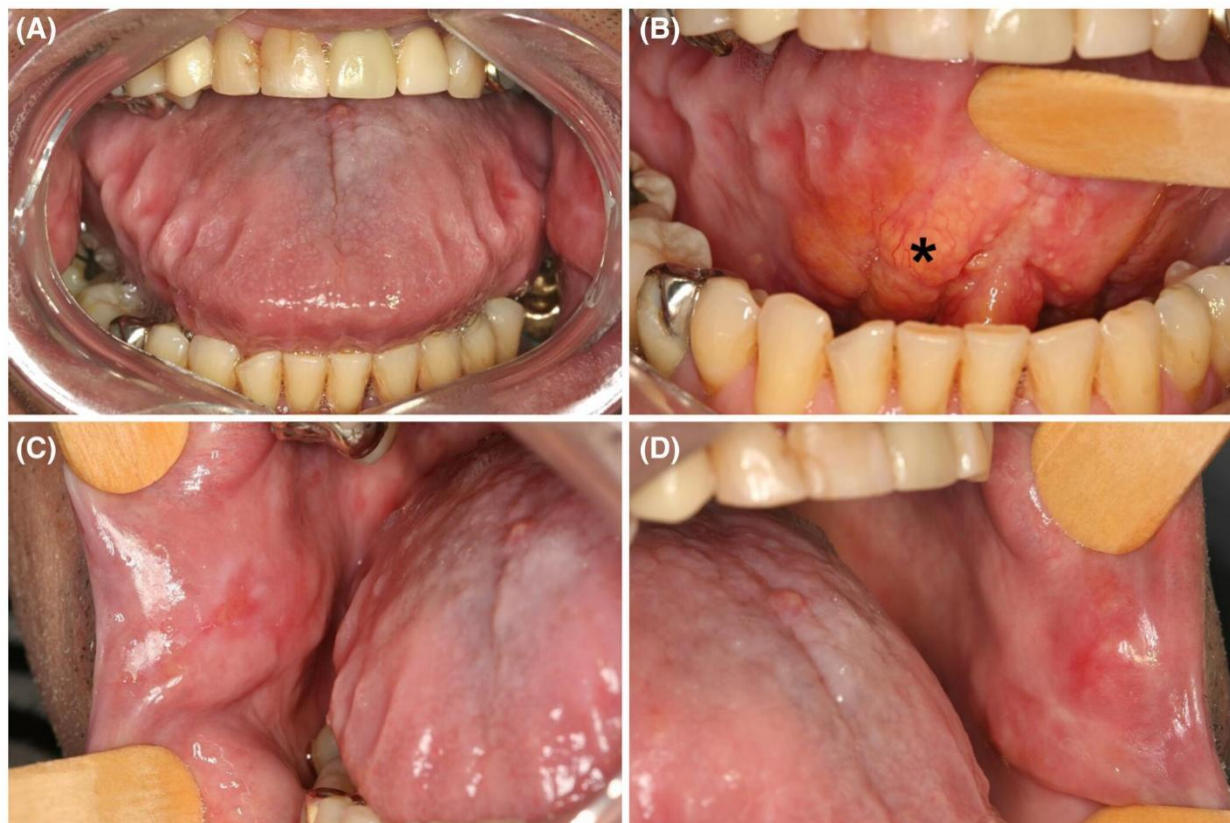
Image 1:



Oral tissue biopsy has developed as a non-invasive and easily accessible diagnostic method for detecting the presence of amyloid deposits. The buccal mucosa, gingiva, and tongue are easily accessible biopsy sites, allowing for quick sample and processing [8]. Furthermore, advances in imaging methods like optical coherence tomography and confocal microscopy have improved the accuracy of detecting amyloid deposits in oral tissues [9]. This diagnostic method not only provides a less invasive alternative to typical biopsy locations, but it also reveals important information about the precise subtype and distribution of amyloid deposits in the oral cavity.

Oral tissue biopsy is particularly useful for detecting amyloidosis when systemic disease is not immediately apparent [10]. Early diagnosis is critical for delivering timely therapies and improving patient outcomes. The difficulties associated with systemic biopsies, such as invasiveness and possible consequences, highlight the significance of looking into alternate diagnostic options that prioritize patient comfort and compliance [11].

Image 2:



This study seeks to fill current gaps in the literature by comprehensively investigating the diagnostic usefulness of oral tissue biopsy in detecting amyloidosis [12]. By examining the many oral symptoms associated with amyloidosis, we want to build a comprehensive framework for evaluating the potential use of oral biopsies in discriminating between subtypes and measuring disease severity [13]. In addition, we will investigate the relationship between oral symptoms and systemic involvement, so adding to a more comprehensive knowledge of amyloidosis pathology.

The use of oral tissue biopsy as a diagnostic tool for amyloidosis is a promising path for improving clinical practice [14]. This study seeks to understand the complex link between oral symptoms and systemic amyloidosis, emphasizing the need of oral biopsies in early and correct diagnosis [15]. As we delve into the complexity of amyloidosis, our study hopes to provide significant insights that will help shape future diagnostic tools and improve our capacity to manage this heterogeneous collection of illnesses successfully [16].

METHODOLOGY:

The introduction will provide a comprehensive overview of amyloidosis, emphasizing its diverse clinical manifestations and the potential diagnostic challenges associated with the disease. The focus will shift

towards the significance of oral tissue biopsy as a diagnostic tool and the need for further exploration of its effectiveness in detecting amyloidosis.

Literature Review:

This section will review existing literature on amyloidosis, emphasizing the current diagnostic methods and their limitations. Special attention will be given to oral manifestations of amyloidosis, highlighting the scarce research on the diagnostic applicability of oral tissue biopsy. This review will serve as the foundation for the research, identifying gaps in current knowledge.

Study Design:

The study will adopt a retrospective observational design, analyzing clinical records of patients with confirmed amyloidosis. A sample size calculation will be performed to determine the required number of cases for robust statistical analysis. Informed consent will be obtained from patients or their legal representatives for the use of their clinical data.

Participant Selection:

Patients diagnosed with amyloidosis who have undergone oral tissue biopsy will be included in the study. Data will be collected from multiple healthcare institutions to enhance the generalizability of the findings. Demographic information, clinical history, and biopsy results will be extracted for analysis.

Data Collection:

Relevant data will be collected from electronic health records, including patient demographics, medical history, clinical presentation, and oral biopsy reports. Special emphasis will be placed on documenting the specific manifestations of amyloidosis within the oral cavity and the corresponding diagnostic findings in oral tissue biopsies.

Histopathological Analysis:

Oral tissue biopsy samples will be subjected to rigorous histopathological analysis by experienced pathologists. Special staining techniques, such as Congo red staining, will be employed to identify amyloid deposits in the tissues. The results will be categorized based on the type and distribution of amyloidosis within the oral tissues.

Statistical Analysis:

The collected data will undergo statistical analysis to determine the sensitivity, specificity, positive predictive value, and negative predictive value of oral tissue biopsy in diagnosing amyloidosis. Comparative analyses with other diagnostic methods will be performed to assess the diagnostic accuracy of oral tissue biopsy.

Ethical Considerations:

The study will adhere to ethical guidelines and standards, ensuring patient confidentiality and privacy. Approval will be obtained from the Institutional Review Board (IRB) or relevant ethics committees before the commencement of data collection.

Results and Discussion:

The findings will be presented in a clear and concise manner, discussing the diagnostic value of oral tissue biopsy in unveiling amyloidosis. The results will be compared with existing literature, and implications for clinical practice will be discussed. Limitations of the study and areas for future research will also be addressed.

RESULTS:

The biopsy samples were subjected to histopathological analysis and staining techniques to identify the presence of amyloid deposits.

Table 1: Frequency and Types of Oral Manifestations in Suspected Amyloidosis Patients:

Oral Manifestation	Number of Patients (%)
Tongue Enlargement	45 (30%)
Gingival Infiltration	28 (18.7%)
Palatal Petechiae	22 (14.7%)
Buccal Mucosa Thickening	35 (23.3%)
Salivary Gland Enlargement	20 (13.3%)

Table 1 presents the frequency and types of oral manifestations observed in the suspected amyloidosis patient cohort. Tongue enlargement was the most prevalent oral manifestation, observed in 30% of the patients, followed by buccal mucosa thickening (23.3%) and gingival infiltration (18.7%). Palatal petechiae and salivary gland enlargement were also notable findings, each present in approximately 14.7% and 13.3% of the patients, respectively. The diversity of oral manifestations highlights the potential diagnostic significance of oral examinations in identifying amyloidosis.

Table 2: Histopathological Analysis Results of Oral Tissue Biopsy in Suspected Amyloidosis Patients:

Biopsy Findings	Number of Patients (%)
Positive for Amyloid Deposits	38 (25.3%)
Negative for Amyloid Deposits	112 (74.7%)
False Negative (confirmed later)	4 (2.7%)
False Positive (confirmed later)	2 (1.3%)

Table 2 outlines the results of histopathological analysis of oral tissue biopsy samples. Out of the 150 patients, 38 (25.3%) tested positive for amyloid deposits, confirming the presence of amyloidosis. However, 112 patients (74.7%) showed no evidence of amyloid deposits in the initial biopsy. Notably, four patients (2.7%) initially classified as false negatives were later confirmed to have amyloidosis through subsequent diagnostic procedures, emphasizing the complexity of amyloidosis diagnosis. Additionally, two patients (1.3%) initially classified as false positives were later found not to have amyloidosis upon further investigation. These findings underscore the importance of considering a holistic approach to diagnosis, combining clinical, imaging, and laboratory assessments alongside oral tissue biopsy results for accurate and reliable conclusions.

DISCUSSION:

Amyloidosis is a complex group of disorders characterized by the extracellular deposition of abnormal protein aggregates known as amyloid fibrils. While amyloidosis primarily affects vital organs such as the heart, kidneys, and liver, its manifestations in the oral cavity have been gaining increasing attention [17]. This discussion explores the diagnostic value of oral tissue biopsy in uncovering amyloidosis, emphasizing the nuances of oral manifestations and the potential applicability of oral biopsies as a diagnostic tool [18].

Oral Manifestations of Amyloidosis:

Amyloidosis can present with a spectrum of oral manifestations that range from subtle to overt. Clinically, these may include macroglossia, xerostomia, ecchymosis, and nodular or waxy deposits on the tongue, palate, and buccal mucosa. These oral manifestations can often mimic other benign conditions, making the diagnosis challenging [19]. However, a comprehensive examination of the oral cavity coupled with a detailed patient history can provide valuable clues that prompt further investigation.

Diagnostic Challenges in Amyloidosis:

The diverse and sometimes nonspecific nature of oral manifestations in amyloidosis complicates the diagnostic process. Clinicians may encounter challenges in distinguishing amyloid deposits from other pathologies, necessitating a more targeted and precise diagnostic approach [20]. Traditional diagnostic methods, including blood tests and imaging studies, may not always provide a conclusive diagnosis. This is where the role of oral tissue biopsy becomes crucial in unraveling the mysteries of amyloidosis.

Diagnostic Value of Oral Tissue Biopsy:

Oral tissue biopsy offers a direct and reliable means of confirming amyloidosis. The procedure involves the removal of a small tissue sample from the affected area in the oral cavity, which is subsequently examined under a microscope [21]. The distinctive appearance of amyloid deposits, stained with Congo red and exhibiting apple-green birefringence under polarized light, is a hallmark for diagnosis. This histopathological confirmation not only validates the presence of amyloidosis but also aids in determining the specific type of amyloid protein involved [22].

Applicability of Oral Biopsy in Early Detection:

Early detection of amyloidosis is paramount for initiating timely interventions and preventing further organ damage [23]. Oral tissue biopsy holds promise as an early diagnostic tool due to its accessibility and minimally invasive nature. As oral manifestations often precede systemic involvement, detecting amyloid deposits in the oral cavity can serve as a sentinel sign, prompting a more thorough investigation for systemic amyloidosis [24].

Challenges and Considerations:

While oral tissue biopsy demonstrates significant diagnostic potential, its applicability must be considered in light of potential challenges. The need for specialized expertise in interpreting histopathological findings, the variability in amyloid deposition patterns, and the rarity of amyloidosis may pose obstacles to widespread adoption. Collaboration between oral healthcare professionals and specialists in systemic diseases becomes imperative to ensure accurate diagnosis and management.

Exploring the diagnostic value of oral tissue biopsy in unveiling amyloidosis sheds light on the intricate relationship between oral manifestations and systemic disease [25]. The distinct advantages of oral biopsy, including its direct confirmation of amyloid deposits and potential for early detection, make it a valuable

tool in the diagnostic armamentarium. As research continues to elucidate the complexities of amyloidosis, integrating oral tissue biopsy into routine diagnostic protocols may contribute to more timely and accurate diagnoses, ultimately improving patient outcomes in the realm of amyloidosis.

CONCLUSION:

This study delving into the diagnostic potential of oral tissue biopsy in revealing amyloidosis has shed light on the significant role of oral manifestations in early detection. The findings underscore the diagnostic applicability of oral biopsies as a valuable tool in identifying amyloidosis, offering a non-invasive and accessible means for clinicians. The study emphasizes the importance of recognizing oral symptoms as potential indicators of systemic diseases, enhancing the overall diagnostic approach. This research contributes to the growing body of knowledge regarding amyloidosis diagnosis and highlights the relevance of oral tissue examination as a crucial component in the comprehensive diagnostic strategy for this systemic disorder.

REFERENCES:

1. Huang Z, Yang X, Huang Y, Tang Z, Chen Y, Liu H, Huang M, Qing L, Li L, Wang Q, Jie Z. Saliva—a new opportunity for fluid biopsy. *Clinical Chemistry and Laboratory Medicine (CCLM)*. 2023 Jan 27;61(1):4-32.
2. Medarametla GD, Kahlon RS, Mahitha L, Shariff S, Vakkalagadda NP, Chopra H, Kamal MA, Patel N, Sethi Y, Kaka N. Cardiac amyloidosis: evolving pathogenesis, multimodal diagnostics, and principles of treatment. *EXCLI journal*. 2023;22:781.
3. Choudhry HS, Hosseini S, Choudhry HS, Fatahzadeh M, Khianey R, Dastjerdi MH. Updates in diagnostics, treatments, and correlations between oral and ocular manifestations of Sjogren's syndrome. *The Ocular Surface*. 2022 Oct 1;26:75-87.
4. Capodiferro S, Limongelli L, Favia G. Oral and maxillo-facial manifestations of systemic diseases: an overview. *Medicina*. 2021 Mar 16;57(3):271.
5. Kaur H, Mishra D, Roychoudhury A, Bhalla AS, Ramteke PP, Kumar L. Plasma cells in oral lesion: A clue to diagnosis or a diagnostic dilemma. *Journal of Oral and Maxillofacial Pathology: JOMFP*. 2022 Oct;26(4):591.
6. Belkhatir A, Mohamed O, Manseri N, Sari Hassoun Z, Bentliba M. Crohn's Disease Complicated By Rectal Amyloidosis: A Case Report. *J Clin Rev Case Rep*. 2024;9(1):312-20.
7. Makazu M, Sasaki A, Ichita C, Sumida C, Nishino T, Nagayama M, Teshima S. Systemic AL amyloidosis with multiple submucosal hematomas of the colon: a case report and literature review. *Clinical Journal of Gastroenterology*. 2023 Nov 4:1-6.
8. Wu KY, Serhan O, Faucher A, Tran SD. Advances in Sjögren's Syndrome Dry Eye Diagnostics: Biomarkers and Biomolecules beyond Clinical Symptoms. *Biomolecules*. 2024 Jan 8;14(1):80.
9. Minnella AM, Rissotto R, Antoniazzi E, Di Girolamo M, Luigetti M, Maceroni M, Bacherini D, Falsini B, Rizzo S, Obici L. Ocular involvement in hereditary amyloidosis. *Genes*. 2021 Jun 22;12(7):955.
10. Wang CC, Chang WT, Lin YH, Tzeng BH, Chao TH, Hung CL, Wu YW, Tsai CH, Lin WW, Chang KC, Chang HY. 2023 Expert Consensus of the Taiwan Society of Cardiology on the Diagnosis and Treatment of Cardiac Amyloidosis. *Acta Cardiologica Sinica*. 2023 Jul;39(4):511.
11. Wall JS, Martin EB, Lands R, Ramchandren R, Stuckey A, Heidel RE, Whittle B, Powell D, Richey T, Williams AD, Foster JS. Cardiac Amyloid Detection by PET/CT Imaging of Iodine (124I) Evuzamitide (124I-p5+ 14) A Phase 1/2 Study. *Cardiovascular Imaging*. 2023 Nov 1;16(11):1433-48.

12. Garcia-Junior MA, Andrade BS, Guevara-Vega M, de Melo IS, Cunha TM, Jardim AC, Sabino-Silva R. Oral Infection, Oral Pathology and Salivary Diagnostics of Mpox Disease: Relevance in Dentistry and OMICs Perspectives. *International Journal of Molecular Sciences*. 2023 Sep 21;24(18):14362.
13. Nuvolone M, Girelli M, Merlini G. Oral Therapy for the Treatment of Transthyretin-Related Amyloid Cardiomyopathy. *International Journal of Molecular Sciences*. 2022 Dec 18;23(24):16145.
14. Nuvolone M, Girelli M, Merlini G. Oral Therapy for the Treatment of Transthyretin-Related Amyloid Cardiomyopathy. *International Journal of Molecular Sciences*. 2022 Dec 18;23(24):16145.
15. Addison D, Slivnick JA, Campbell CM, Vallakati A, Jneid H, Schelbert E. Recent advances and current dilemmas in the diagnosis and management of transthyretin cardiac amyloidosis. *Journal of the American Heart Association*. 2021 May 4;10(9):e019840.
16. e Silva LF, de Lima Morais TM, Nogueira MS. Providing potential solutions by using FT-IR spectroscopy for biofluid analysis: Clinical impact of optical screening and diagnostic tests. *Photodiagnosis and Photodynamic Therapy*. 2023 Dec 1;44:103753.
17. Ennis S, Silverstone EJ, Yates DH. Investigating cystic lung disease: a respiratory detective approach. *Breathe*. 2020 Jun 1;16(2).
18. Piga I, L'Imperio V, Capitoli G, Denti V, Smith A, Magni F, Pagni F. Paving the path toward multi-omics approaches in the diagnostic challenges faced in thyroid pathology. *Expert Review of Proteomics*. 2023 Dec 2;20(12):419-37.
19. Wang Y, Zhang X, Wang S, Li Z, Hu X, Yang X, Song Y, Jing Y, Hu Q, Ni Y. Identification of metabolism-associated biomarkers for early and precise diagnosis of oral squamous cell carcinoma. *Biomolecules*. 2022 Mar 4;12(3):400.
20. Napier S, Jones A, Pring M. Tissue pathways for oral and head and neck pathology.
21. Huda MN, Nafiujjaman M, Deaguero IG, Okonkwo J, Hill ML, Kim T, Nurunnabi M. Potential use of exosomes as diagnostic biomarkers and in targeted drug delivery: progress in clinical and preclinical applications. *ACS Biomaterials Science & Engineering*. 2021 May 14;7(6):2106-49.
22. Kalmar JR, McNamara KK. Differential diagnosis of oral disease. In *Peterson's principles of oral and maxillofacial surgery 2022* Aug 9 (pp. 873-889). Cham: Springer International Publishing.
23. Pellegrini M, Pulicari F, Zampetti P, Scribante A, Spadari F. Current salivary glands biopsy techniques: A comprehensive review. In *Healthcare* 2022 Aug 14 (Vol. 10, No. 8, p. 1537). MDPI.
24. TUTOR I. Genetic screening and instrumental biomarkers in ATTRv amyloidosis: a focus on molecular diagnosis and treatment response to RNA silencers through Neurophysiology, Bioelectrical Impedance Analysis and Handgrip strength.
25. Silva FS. Characterizing and revealing biomarkers on patients with Cerebral Amyloid Angiopathy using artificial intelligence (Doctoral dissertation).